

## Management of Localized Gingival Overgrowth in Patient under Fixed Orthodontic Treatment: A Case Report

Neira N. Sakinah, Yuliana M. D. Arina, Depi Praharani, Peni Pujiastuti, Desi S. Sari, Melok A. Wahyukundari

Department of Periodontics, Faculty of Dentistry, Universitas Jember, Jember, Indonesia  
Email: [neirasakinah@unej.ac.id](mailto:neirasakinah@unej.ac.id)

Received: April 25, 2022; Accepted: June 10, 2022; Published on line: June 17, 2022

**Abstract:** Recently, the need for orthodontic treatment has increased along with the increasing need and public awareness of the importance of dental and oral health. During treatment, problems sometimes occur with periodontal tissue. Orthodontic devices that bond to the tooth surface can cause difficulties in controlling plaque, especially in marginal areas which can cause inflammation and gingival overgrowth. Too high tensile strength and weak tissue capacity are also the factors that can cause gingival overgrowth. This case report described the management of gingival growth in a patient under fixed orthodontic treatment. We reported an 18-year-old female patient with a good systemic condition that had gingival overgrowth localized on the anterior part of mandibula. The surgical intervention was performed by using conventional surgical methods. Its goal was to remove the gingival pocket, therefore, the plaque could be easily controlled. The use of a scalpel was considered very effective for eliminating excessive gingiva. Two weeks after surgical treatment, the gum resulted in good repair. The continuity of orthodontic treatment could be achieved properly after 3-month surgical treatment. Instructions and motivation to maintain oral hygiene were important to avoid recurrence. In addition, multidisciplinary dentistry between orthodontist and periodontist was needed to achieve a better result.

**Keywords:** gingival overgrowth; gingivectomy; orthodontic appliance

### INTRODUCTION

Orthodontic treatment in this decade has increased frequently along with the increasing need and public awareness of the importance of dental and oral health. Crowded teeth can cause various dental and oral health problems such as periodontal disease, problems with mastication, problems with the temporomandibular joint (TMJ), halitosis, cavities, and oral health-related quality of life.<sup>1-3</sup> With orthodontic treatment, complications that occur due to crowding of teeth can often be resolved or at least prevent the severity of the disease. Proper alignment of teeth and harmonious occlusal and jaw relationships will make it easier to control plaque when compared to crowded teeth. Thus, plaque control can be performed adequately.

Besides the benefits of orthodontic treatment, it has the potential to cause side effects.

Orthodontic devices can cause gingival disease. Moreover, if the disease is not well undertaken it can become more serious. The severity of the destruction can lead to periodontal disease. The most common impact during orthodontic treatment is gingival overgrowth. The relationship between orthodontic treatment and gingival growth has been widely studied.<sup>4-6</sup>

Gingival overgrowth during orthodontic treatment may occur due to increased plaque accumulation. Studies show that fixed orthodontic placement has the potential to cause microbiological environment changes in quantity and quality in the area around the bracket.<sup>7</sup> On the other hand, individuals under orthodontic treatment require more skill and effort to control their oral hygiene, especially on the proximal surface of the teeth.<sup>5</sup> If plaque control is not carried out

adequately, it can cause a negative response in the tissues such as gingival overgrowth. Eid et al<sup>4</sup> in their research explained that individuals with low plaque control had the highest percentage of gingival growth.

Materials used during orthodontic treatment have the potential to initiate gingival overgrowth. A recent study explained that a continuous low dose of nickel released from orthodontic appliances to the epithelium was the initiating factor in gingival overgrowth.<sup>7</sup> The average orthodontic appliance uses nickel-titanium (NiTi) as its base material. Excess cement around orthodontic brackets has also been associated with gingival overgrowth, especially in the anterior region.<sup>5</sup> In addition, the cooperation of patients in the control of orthodontic treatment is also a factor in the occurrence of gingival overgrowth. The movement strength of orthodontic appliances is not well controlled when the patient does not visit the orthodontist according to the specified time.

The management of gingival overgrowth can be done with non-surgical and surgical treatment. Non-surgical treatment includes oral hygiene instructions and motivation, scaling, root planing, and oral prophylaxis.<sup>8,9</sup> Oral hygiene instruction and motivation are the important ones to build up the personal oral hygiene, so that can decrease the disease recurrence. This basic treatment can give the best result and it is also a cost-effective approach and a simple way to do it by the patient. In some cases, surgical treatment is needed if there is incomplete resolution after non-surgical treatment.<sup>7</sup> This case report presents a case of gingival overgrowth in a patient under fixed orthodontic treatment and the explanation of its management.

## CASE REPORTS

An 18-year-old woman came to the Periodontics Clinic of Jember University Dental and Oral Hospital for a referral from an orthodontist. The orthodontist referred the patient for treatment of localized gingival overgrowth on teeth 31, 32, and 33. Based on anamnesis, the patient had been experiencing this condition for approximately five months. Gingival overgrowth did not subside and was

getting bigger. The gums in that area bled several times when the patient brushed her teeth. The patient was under orthodontic treatment since a year ago and did not regularly visit the orthodontist according to the schedule. The patient did scaling and root planning approximately a year ago. The patient stated that she brushed her teeth twice a day in the morning and evening, and had no history of systemic disease or allergies to certain drugs or foods.

Objective examinations were carried out to establish the diagnosis and determine the prognosis and the treatment plan, so that, the treatment could provide good results. Objective examination revealed an oral hygiene index-simplify (OHI-s) of 2.17 which was included in the category of moderate oral hygiene, bleeding on probing (BOP) more than 60% of the gingival area in the oral cavity, calculus in almost all teeth, gingival overgrowth on teeth 31, 32 and 33 (Figure 1A) with an average probing depth (PD) of 4 mm, gingival index (GI) score was 2, and gingival encroachment (GE) score was 3.

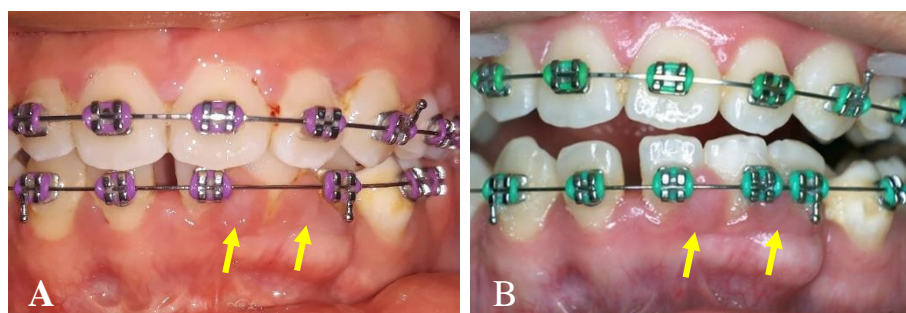
The management of gingival overgrowth in this case included two phases, namely the non-surgical phase and the surgical phase. The non-surgical phase of treatment included oral hygiene instructions and motivation, scaling, root planing, oral prophylaxis, and additional use of mouthwash. After two weeks of the nonsurgical phase of treatment, the patient came back for control. Objective examination during control showed persistent gingival overgrowth with fibrotic type on teeth 31, 32, 33 (Fig. 1B). The mean probing depth was 4 mm, GI score was 1, and GE score was 2. Therefore, a follow-up visit was planned for surgical treatment.

The surgical treatment was gingivectomy and gingivoplasty (Fig. 2A-F). Gingivectomy was performed conventionally using a scalpel. At this stage, an assessment of vital signs was carried out and the patient was asked to sign an informed consent. Vital signs showed normal results, with blood pressure 110/70 mmHg, pulse 78x/minute, respiration 24x/minute, and body temperature 36.4°C. The initial stage of gingivectomy was asepsis and isolation of the work area

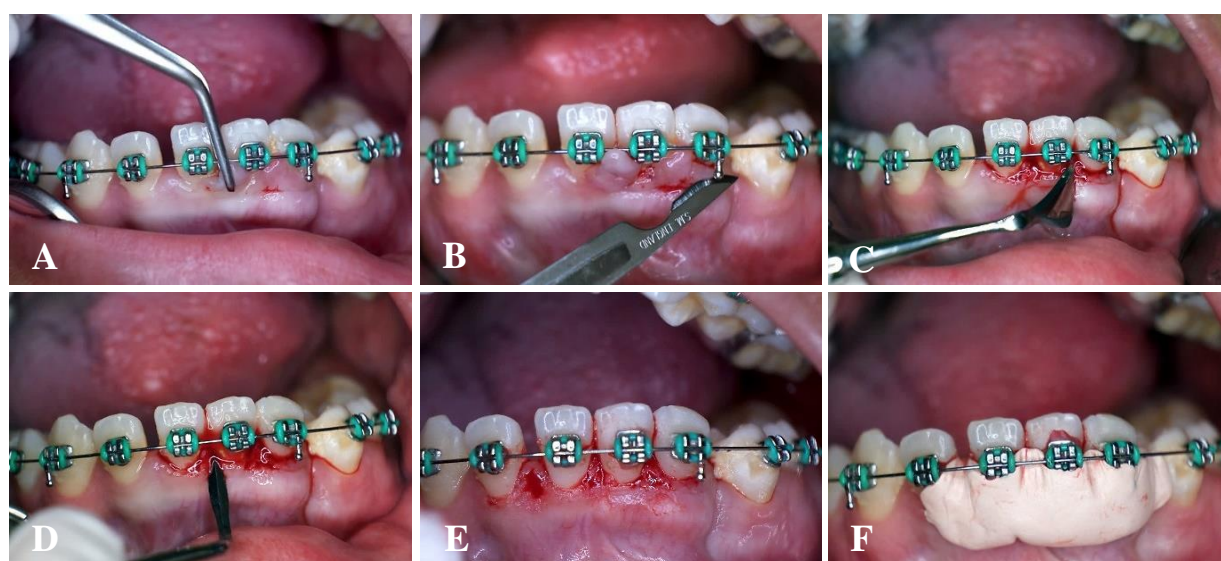
and continued with local anesthesia in the labial area of teeth 31 and 33 using lidocaine containing adrenaline. After the anesthetic had worked, a bleeding point was made using pocket marking forceps (PMF) to mark the bottom of the pocket and used as a reference for the limit of gingival cutting. The excess gingiva was then incised using a surgical blade and the gingiva was excised using a Gracey curette. This was followed by a gingivoplasty procedure using a Kirkland knife for the facial area and an Orban knife for the interdental area. After the gingivoplasty procedure, the gingiva was irrigated with 0.9% NaCl and dried. Then the appli-

cation of the periodontal pack on the post-surgical wound using a pack containing zinc oxide non-eugenol. The patient was then given postoperative instructions, analgesic, and instruction for control seven days after the surgical treatment.

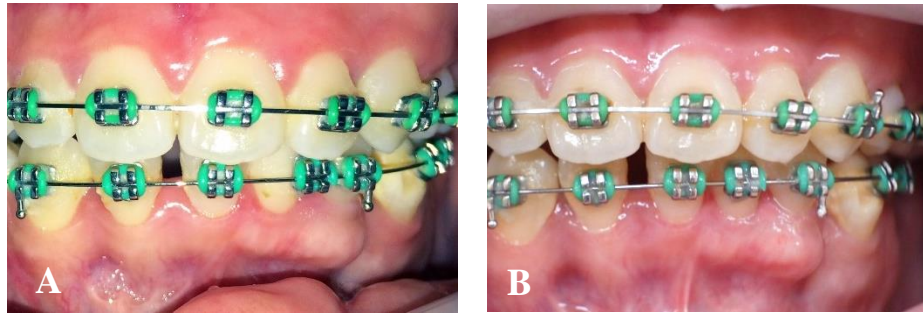
At a week after surgical treatment, the periodontal pack was removed and irrigated using 0.9% NaCl. The results of the clinical examination showed that the post-surgical area still looked red. The patient was instructed to maintain oral hygiene by using extra soft bristles and mouthwash, and for further control at seven days later.



**Figure 1.** Clinical condition before gingivectomy. A) At the initial visit, there was localized gingival overgrowth on teeth 31, 32, and 33 indicated by the yellow arrow; B) After two weeks of nonsurgical treatment, the localized gingival overgrowth with fibrotic type was still persistent on teeth 31, 32, and 33 indicated by the yellow arrow



**Figure 2.** Steps of surgical treatment. A) Marking the bleeding point using a PMF pocket; B) Gingivectomy using a surgical blade; C) Gingivoplasty using Kirkland knife for the facial area; and D) Orban knife for the interdental area; E) Results of gingivectomy and gingivoplasty; F) Periodontal pack application using zinc oxide non-eugenol pack



**Figure 3.** Clinical condition after gingivectomy. A) Two weeks after surgical treatment; B) Three month follow-up after surgical treatment (final result)

The results of examination at two weeks after surgical treatment showed that there was no redness in the postoperative area and the gingival healing was complete (Fig. 3A). The patient was instructed to maintain oral hygiene and come for further control after three months.

Three months after surgical treatment, the patient came for further control. The results of the examination showed that there was no recurrence of gingival overgrowth, an OHI-score of 1 which was included in the category of good oral hygiene, and BOP of more than 30% of the gingival area in the oral cavity (Figure 3B). The patient was instructed to maintain her oral hygiene, then was referred to the orthodontist for continuation of the fixed orthodontic treatment with accompanying notes to motivate the patient to control according to the specified time, therefore, the movement strength of orthodontic appliances could be controlled properly and the patient's level of oral hygiene could be evaluated regularly. Thus, it was hoped that there would be no recurrence of gingival overgrowth.

## DISCUSSION

The gingival overgrowth category in this case report is GE 3 with fibrotic type. GE 3 is marked overgrowth that describes by the presence of encroachment of the gingiva onto the clinical crown. The contour of the gingival margin is convex rather than concave. Gingival overgrowth has a buccolingual dimension of approximately 3 mm or more, measured from the tip of the papilla outward. The papilla is retractable.<sup>10</sup> This gingival overgrowth is related to the use of orthodontic appliances

during orthodontic treatment.

Orthodontic treatment can increase the prevalence of gingival overgrowth. This can occur due to the influence of several risk factors for the use of orthodontic appliances, including the following: plaque control,<sup>4,5</sup> changes in microbiological environment,<sup>7</sup> uncontrolled orthodontic movement strength and unfavorable tissue reaction during tooth movement,<sup>11</sup> mechanical effects of orthodontic bands and chemical effects of excess bracket cement,<sup>5</sup> and nickel content in an orthodontic appliance.<sup>7,12</sup>

Plaque control becomes more difficult and the patient is inadequate in maintaining oral hygiene. Individuals with the use of orthodontic appliances require more skill and effort to control their oral hygiene, especially on the proximal surfaces of the teeth.<sup>5</sup> Eid et al<sup>4</sup> explained in their research that individuals with low plaque control had the highest percentage of gingival growth. In addition, the patient in this case report belonged to a young age where the patient tended to be less compliant with treatment and pay less attention to oral hygiene. This is supported by the results of Eid et al research<sup>4</sup> which explains that the highest frequency of GE was observed among the age group 10-19 years.

Concerning the changes in the microbiological environment, the increase in pocket depth (PD) at the gingival overgrowth can reflect the presence of gingival pockets, which create an ecologic environment that favors a qualitative shift from a predominance of aerobic Gram-positive cocci to more putative periodontal pathogens, anaerobic Gram-negative species.<sup>7</sup>

About uncontrolled orthodontic movement strength and unfavorable tissue reaction during tooth movement,<sup>11</sup> the patient in this case report is known to rarely go to an orthodontist for control. The strength of the movement of orthodontic appliances becomes uncontrolled if the patient does not make regular visits to the orthodontist according to the specified time.

Related to mechanical effects of orthodontic bands and chemical effects of excess bracket cement, Zanatta et al<sup>5</sup> in their research explained that excess resin around orthodontic brackets can initiate gingival overgrowth, especially in the anterior area. Excessive resin becomes a place for plaque and debris retention, thus creating a favorable environment for bacteria.

Concerning nickel content in an orthodontic appliance, a recent study explained that a continuous low dose of nickel released from orthodontic appliances to the epithelium was the initiating factor in gingival overgrowth.<sup>7</sup> The average orthodontic appliance uses nickel-titanium (NiTi) as its base material. This finding is also supported by other studies which confirm that chronic exposure to nickel from orthodontic appliances can cause gingival enlargement.<sup>12</sup>

The management of gingival overgrowth can be done with non-surgical and surgical treatment. Non-surgical treatment includes oral hygiene instructions and motivation, scaling, root planing, and oral prophylaxis. Oral hygiene instruction and motivation are the important ones to build up the personal oral hygiene, so that can decrease the disease severity.<sup>8,9</sup> This finding is also in agreement with the literature stating that increased oral hygiene awareness decreases plaque retention and enhances gingival health during fixed orthodontic treatment.<sup>4</sup>

Examination at the control of two weeks after non-surgical treatment revealed that the gingival overgrowth was still persistent. These results are consistent with the findings of several pieces of literature which explain that complete healing of orthodontic treatment-induced gingival overgrowth is not always achieved by the temporary removal of the orthodontic appliance, scaling and root

planing, or increasing oral hygiene. This is due to fibrotic changes in the gingival connective tissue. Non-surgical periodontal treatment can remove the inflamed gingival overgrowth. However, gingival overgrowth with fibrotic changes cannot be corrected simply by eliminating irritating factors, such as bacterial plaque, archwire, and brackets. In such cases, surgical intervention is indicated if there is no improvement of the gingival overgrowth after non-surgical periodontal treatment.<sup>7,12</sup> Therefore, surgical treatment was required by the patient in this case report.

Surgical treatments include gingivectomy and gingivoplasty. In this case report, gingivectomy and gingivoplasty were performed using the conventional technique with a scalpel and this technique resulted in effective gingival reduction. Then control was done after a week and two weeks post-surgery. Complete healing of the gingival surface was seen at the two weeks post-operative control. Follow-up at three months after surgical treatment showed satisfactory healing with no clinical signs of recurrence. We decided to refer the patient back to the orthodontist for continuing her orthodontic treatment with some suggestions to minimize the recurrence and another impact that might occur of using fixed orthodontic appliances on the periodontal tissue. The suggestions given include: 1) motivate the patient about the importance of maintaining oral hygiene; 2) considering the tissue-adaptable pressure of the orthodontic appliance; 3) emphasize the patient to control regularly, so, the pressure of the orthodontic appliance can be controlled properly;<sup>11</sup> use brackets that are adjusted to the size of the patient's teeth so that they are not too large, especially in the anterior mandibular area. Therefore, the plaque control in the interdental area will be easier; and periodic recall every 3 months for proper periodontal treatment.<sup>12</sup>

## CONCLUSION

The continuity of orthodontic treatment can be achieved properly after three months of surgical treatment. Instructions and motivation to maintain oral hygiene are important to be given to avoid recurrence. In addition,

multidisciplinary dentistry between orthodontist and periodontist is needed to achieve a better result of treatment.

### Conflict of Interest

The authors declare that there is no conflict of interest regarding the publication of this case report study.

### REFERENCES

1. Anthony SN, Zimba K, Subramanian B. Impact of malocclusions on the oral health-related quality of life of early adolescents in Ndola, Zambia. *Int J Dent*. 2018;2018:7920973. Doi: 10.1155/2018/7920973.
2. Javali MA, Betsy J, Al Thobaiti RSS, Alshahrani RA, AlQahtani HAH. Relationship between malocclusion and periodontal disease in patients seeking orthodontic treatment in Southwestern Saudi Arabia. *Saudi J Med Med Sci [Internet]*. 2020; 8(2):133–9.
3. Kolawole KA, Folayan MO. Association between malocclusion, caries and oral hygiene in children 6 to 12 years old resident in suburban Nigeria. *BMC Oral Health*. 2019;19(1):1–9.
4. Eid HA, Assiri HA, Kandyala R, Togoo RA, Turakhia VS. Original research gingival enlargement during fixed orthodontic treatment. *J Int Oral Heal*. 2014;6(1):1–4.
5. Zanatta FB, Ardenghi TM, Antoniazzi RP, Pinto TMP, Rösing CK. Association between gingivitis and anterior gingival enlargement in subjects undergoing fixed orthodontic treatment. *Dental Press J Orthod*. 2014;19(3):59–66.
6. Pinto AS, Alves LS, Zenkner JE do A, Zanatta FB, Maltz M. Gingival enlargement in orthodontic patients: Effect of treatment duration. *Am J Orthod Dentofac Orthop*. 2017;152(4):477–82.
7. Gong Y, Lu J, Ding X. Clinical, microbiologic, and immunologic factors of orthodontic treatment-induced gingival enlargement. *Am J Orthod Dentofac Orthop [Internet]*. 2011;140(1):58–64.
8. Prabhu M, Ramesh A, Thomas B. Treatment of orthodontically induced gingival hyperplasia by Diode laser - case report. *J Heal Allied Sci NU*. 2015;05(02):066–8.
9. Jadhav T, Bhat KM, Bhat GS, Varghese JM. Chronic inflammatory gingival enlargement associated with orthodontic therapy--a case report. *J Dent Hyg*. 2013; 87(1):19–23.
10. Majdiah Wan Mohamad W, Izzati Mat Zaid S, Taib H. Assessment of gingival status and gingival overgrowth among immunosuppressed patients in Universiti Sains Malaysia Hospital. *J Dent Indones*. 2021;28(1):27–32.
11. Lastianny SP. Dampak pemakaian alat ortodontik terhadap kesehatan jaringan periodontal. *Majalah Kedokteran Gigi Indonesia*. 2012;19(2):181–4.
12. Khamar PB, Bargale S, Dave BH, Yadav TEJ. Recurrent localized chronic gingival enlargement in fixed orthodontic treatment - a novel case report. *Eur J Dent Ther Res*. 2014;3(1):192–4.