

Clinical Response Difference between Acyclovir and Valacyclovir in Recurrent Intraoral Herpes: Adaptation Treatment in Pandemic Situation

Theodora A. Dwiarie,¹ Wahyu Hidayat,² Dewi Zakiawati²

¹Oral Medicine Residency Program, Universitas Padjadjaran, Bandung, Indonesia

²Oral Medicine Department, Universitas Padjadjaran, Bandung, Indonesia

Email: theodoraadhistydwiarie@gmail.com

Received: March 7, 2022; Accepted; May 19, 2022; Published on line: May 25, 2022

Abstract: Recurrent intraoral herpes (RIH) is a reactivation of herpes simplex virus 1 (HSV 1) and is treated with an antiviral. In this pandemic situation, limited access to health care may lead to many consequences. This case report reports the difference in clinical response between acyclovir and valacyclovir in RIH and treatment in the pandemic situation. A 24 years old man complained of ulcers and pain in the mouth in the last two weeks. The patient had a history of recurrent ulcers since a year ago. Intraoral examination showed multiple ulcers, with erythema halo, 0.2-0.3 cm in diameters on the tongue, uvula, and pharynx. The patient had difficulty in eating. The IgG anti-HSV 1 test showed a positive result, and the lesions were diagnosed as RIH. The patient was treated with acyclovir, benzylamine HCl, and vitamin B12. One month after treatment, the lesions improved, but new lesions still emerged. Therefore, valacyclovir was substituted for acyclovir. Since the patient had difficulty in going to the hospital due to the lockdown policy, medication for two weeks was prescribed for him. One month after treatment with valacyclovir, there was no more new lesion emerging. In conclusion, there was a difference in clinical response between acyclovir and valacyclovir. It is assumed that the patient has resistancy to acyclovir which resulting in poor improvement. The pandemic condition forces us to be flexible in handling patients and adapting to government conditions and rules.

Keywords: recurrent intraoral herpes; acyclovir; valacyclovir

INTRODUCTION

Herpes virus is a DNA virus that can cause various diseases in the oral cavity.¹ One of the herpes virus families often found in humans is herpes simplex virus (HSV) types 1 and 2, with a prevalence of 60% to 90%.² HSV 1 is associated with oral cavity infections, while HSV 2 is associated with genital infections.² HSV 1 lesions can appear on the lips, oral mucosa, and tongue, and last for a week to 10 days.³ Herpetic lesions appear as vesicles and then they rupture, leaving ulcerated lesions.⁴ Antivirals including acyclovir and valacyclovir can help patients to recover.⁵

Treatment of patients with oral lesions, such as HSV1, may be disrupted due to the COVID-19 pandemic.⁶ The pandemic that has been going on since March 2020 has led

to the emergence of various government regulations to reduce the spread of Covid-19.⁷ Uncertain pandemic conditions made dentists must be able to adapt to patient care.

This case report discussed the difference in clinical response between acyclovir and valacyclovir in HSV 1 infection and adaptation treatment in the pandemic situation.

CASE REPORT

A 24-year-old male came to the oral medicine department with complaints of ulcers on the side of the tongue and throat that appeared two weeks ago. He had history of ulcers since one year ago. The patient worked as a teacher and claimed to experience much stress, especially during the Covid-19 pandemic. The patient had been to several dentists and general practitioners and was given

mouthwash and antibiotics, but there was no improvement. During the intraoral examination, multiple ulcers were found on the anterior and lateral of the tongue as well as on the pharynx. Based on the oral examination, this patient was suspected as recurrent intraoral herpes with a differential diagnosis of acute pharyngitis. The patient was advised to take routine blood tests, anti-HSV 1 IgG and IgM tests. Alloclair mouthwash, benzydamine HCl, vitamin B12, and folic acid were prescribed for the patient.

On the second visit a week later, the patient informed that the complaints had improved. However, new ulcers appeared on the left front part of the tongue. The laboratory examination showed that the results of routine blood tests were normal. The anti-HSV 1 IgG test was positive with a value of 97.8 (positive reference value >25) and the IgM test was 0.3 which confirmed the diagnosis of recurrent intraoral herpes. Alloclair and benzydamine were discontinued. Vitamin B12 and folic acid were still consumed added with acyclovir 200 mg 5 times a day.

On the third visit a week later, complaints of ulcers on the tongue still remained with VAS value of 9, which did not decrease. New painful ulcers appeared on the right inner lip. Therefore, the dose of acyclovir was increased to 400 mg 5 times a day added with benzydamine HCl before meals to overcome the pain while eating.

On the fourth visit, the complaints of ulcer on the left tongue decreased, but a new ulcer appeared on the right buccal mucosa. Ulceration on the left lateral tongue improved and ulceration on the lower lip mucosa healed. We suspected that the patient did not use acyclovir as recommended 5 times a day which was inconvenient for the patient. Therefore, acyclovir was discontinued and replaced with valacyclovir 500 mg twice a day. Medication was prescribed for 2 weeks due to lockdown policy which made it difficult for the patient to pay a visit.

On the fifth visit, two weeks after using valacyclovir, there was no new complaints. Intraoral examination showed that the lesion healed and no new ulcers appeared.

DISCUSSION

Herpes simplex virus 1 is the cause of recurrent intraoral herpes (RIH).¹ HSV can become latent in the trigeminal nerve ganglion and be reactivated due to several factors such as stress, fatigue, trauma, age, sun exposure, and immunocompromised conditions.^{2,8} In this patient, we suspect that the leading cause of reactivation of the HSV virus is stress due to workload and pandemic condition. Such condition is usually self-limiting after two weeks.¹ However, this healing does not occur in the patient because of the stress that occurs continuously.

HSV 1 infection can occur in the oral mucosa, oropharynx, and skin above the waist.^{1,8} The recurrence of HSV infection often appears on the lips and keratinized mucosa but does not rule out the possibility of appearing on another oral mucosa such as the tongue.⁸ RIH usually presents with clustered vesicles that rupture and leave ulcers.^{3,4} The same clinical picture was seen in this patient with ulcerated lesions on the oropharynx, tongue, buccal mucosa, and labial mucosa.

The diagnosis of RIH is usually confirmed from the patient's history and clinical condition.¹ HSV 1 and 2 can be identified based on their specific antibodies.⁸ The patient had an increase in anti-HSV 1 IgG antibody almost 4 times the reference value which indicates the presence of chronic infection caused by HSV1.

Treatment of HSV infection depends on the severity.³ Mouthwash can be prescribed to reduce pain and antivirals in hopes of reducing symptoms.^{3,5} The patient was given benzydamine HCl mouthwash to reduce pain, therefore, he could enjoy his meal.⁹

Antiviral drugs commonly given for oral herpes infections are acyclovir and valacyclovir, with acyclovir being the first line antiviral.^{1,5} These drugs can inhibit viral DNA synthesis and replication.² As a substrate for viral DNA polymerase, acyclovir triphosphate competes with deoxyguanosine triphosphate and is integrated into viral DNA, causing premature DNA chain termination.¹⁰ The dose of acyclovir can vary from 200 mg to 500 mg, given five times a day because of its short half-life.^{1,8,11} In this case,

we gave him 200 mg 5 times a day as initial therapy and hoping that acyclovir would increase the healing speed of ulcers and decrease new lesions.

Due to the slow healing and the emergence of new ulcers, we decided to

increase the dose of acyclovir to 500 mg 5 times a day. Acyclovir is usually effective to treat herpes simplex virus.⁸ However, despite increasing the dose of acyclovir, the patient still got new lesions.

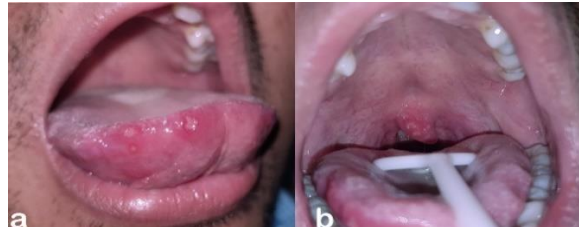

Figure 1. First visit, multiple ulcers on the tongue (a) and pharynx (b)

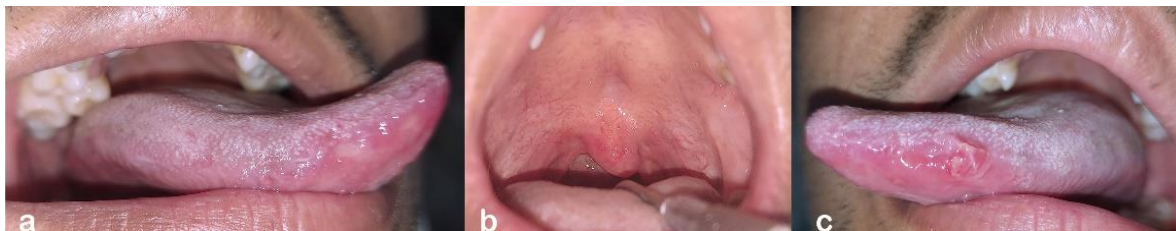


Figure 1. Second visit, healing of the right lateral tongue (a) and pharynx (b); new ulcer on the left lateral tongue (c)

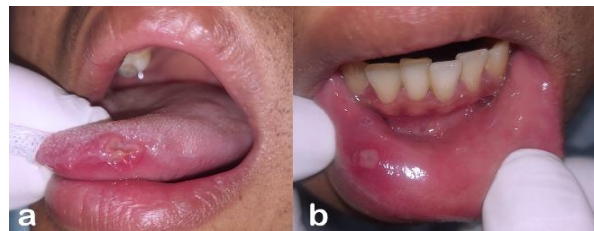

Figure 3. Third visit, ulcer on the left lateral tongue (a) had not yet healed, and a new ulcer appeared on the lower lip mucosa (b)

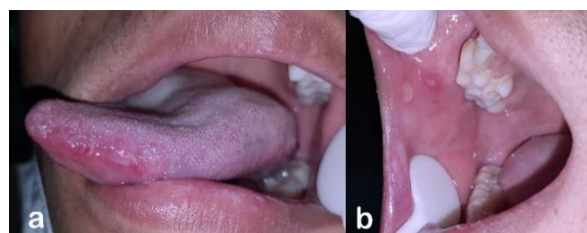


Figure 2. Fourth visit, lesion on the left lateral tongue healed (a) and a new ulcer appeared on the right buccal mucosa (b)

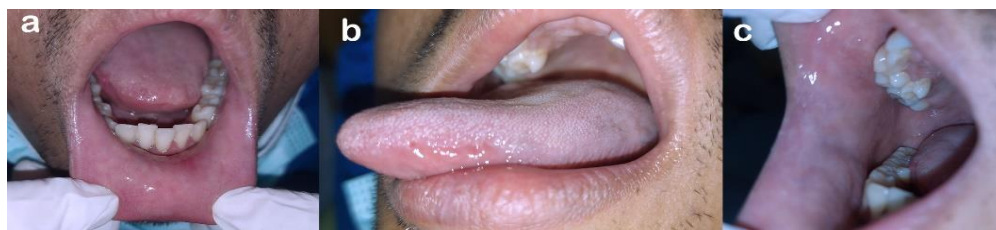

Figure 3. Fifth visit, after using valacyclovir, there were no lesions on the lower labial mucosa (a), left lateral tongue (b), and right buccal mucosa (c)

Acyclovir has a low solubility in water and after oral administration the bioavailability is low, with 85% stay in unmetabolized form, needing relatively more frequent administration to achieve viral suppression.^{12,13} This can make the patient level of compliance decreased.¹⁴ Therefore, we replaced the antivirus with valacyclovir due to its more convenient dosing.⁴

Valacyclovir is a prodrug, that converts to acyclovir rapidly after oral administration and has plasma concentrations 3–5 times higher than acyclovir.^{4,11,15} Valacyclovir had the same mechanism of action as acyclovir but have higher oral bioavailability up to 70%.¹³ The use of valacyclovir at a dose of 1g per day can reduce symptoms of infection and reduce viral shedding.³ Valacyclovir had a longer duration of action and 7 to 10 days of valacyclovir is recommended.^{8,11}

The lockdown conditions imposed by the government caused us to prescribe valacyclovir 500 mg 2 times a day for two weeks. In addition to the lockdown conditions, the patient refused to control through telemedicine because he had an unpleasant experience with telemedicine. The patient has tried to consult various doctors through telemedicine, but the condition of his oral cavity has not improved. In dealing with this condition, we asked the patient to control after two weeks. After using valacyclovir for two weeks, the patient came back and showed healing of the ulcer and no new lesion.

We believe that the patient used the drug regularly because it is more convenient to use valacyclovir 2 times daily. This result in an improvement in the clinical response. Another case report also showed improvement in herpetic lesion after switching drugs from acyclovir to valacyclovir due to patient's low obedience.¹⁶

CONCLUSION

In recurrent intraoral herpes caused by the herpes simplex virus 1, acyclovir is the first line therapy. However, valacyclovir can be used to replace acyclovir if there is no clinical improvement in the patient after treated with acyclovir.

Uncertain pandemic conditions with many new regulations that have undergone many changes, have made it difficult for patients to get the utmost care. This condition encourages dentists to be more flexible in providing care including using teledentistry.

Conflict of Interest

None to be declared.

Acknowledgement

The authors would like to thank the patient for agreeing to be a part of this case report.

REFERENCES

1. Ballyram R, Wood N, Khammissa R, Lemmer J, Feller L. Oral diseases associated with human herpes viruses: Aetiology, clinical features, diagnosis and management. *South African Dent J.* 2016;71(6):253-9.
2. Jiang YC, Feng H, Lin YC, Guo XR. New strategies against drug resistance to herpes simplex virus. *Int J Oral Sci.* 2016; 8(1):1-6.
3. Basavarajappa S, Ramakrishnaiah R, Durgesh B, Al Kheraif AA, Divakar DD. Oral infections of herpes simplex virus: Symptoms, diagnosis, treatment and pathophysiology in periodontal disease. *Rev Med Microbiol.* 2015;26(4):138-42.
4. Stoopler ET, Balasubramaniam R. Topical and systemic therapies for oral and perioral herpes simplex virus infections. *J Calif Dent Assoc.* 2013;41(4):259-62.
5. Crimi S, Fiorillo L, Bianchi A, D'amico C, Amoroso G, Gorassini F, et al. Herpes virus, oral clinical signs and qol: Systematic review of recent data. *Viruses.* 2019;11(5):1-18.
6. Dzedzic A, Varoni EM. Challenges of oral medicine specialists at the time of COVID-19 pandemic. *Oral Dis.* 2020; 00:1-4.
7. Cucinotta D, Vanelli M. WHO declares COVID-19 a pandemic. *Acta Biomed.* 2020;91(1):157-60.
8. Chowdhury S, Chakraborty P pratim. Universal health coverage - There is more to it than meets the eye. *J Fam Med Prim Care.* 2017;6(2):169-70.
9. Kakoei S, Pardakhty A, Hashemipour M-A-S, Larizadeh H, Kalantari B, Tahmasebi E.

- Comparison the pain relief of amitriptyline mouthwash with benzydamine in oral mucositis. *J Dent (Shiraz, Iran)*. 2018;19(1):34-40.
10. Whalen K. Lippincott Illustrated Reviews: Pharmacology South Asian Edition. Philadelphia: Wolters Kluwer; 2019.
 11. Katzung BG, Kruidering-Hall M, Trevor AJ. Pharmacology Examination & Board Review (12th ed). New York: McGraw-Hill Education; 2019. p. 592.
 12. Andrei G, Snoeck R. Advances and perspectives in the management of varicella-zoster virus infections. *Molecules*. 2021; 26(1132).
 13. Rajalakshmi R, Kumari R, Thappa DM. Acyclovir versus valacyclovir. *Indian J Dermatol Venereol Leprol*. 2010;76(4): 439-44.
 14. Modi S, Van L, Gewirtzman A, Mendoza N, Bartlett B, Tremaine AM, et al. Single-day treatment for orolabial and genital herpes: A brief review of pathogenesis and pharmacology. *Ther Clin Risk Manag*. 2008;4(2):409-17.
 15. Mostofa MK, Sen KG, Sarkar SK, Uddin MM, Begum K, Ahmed K. Efficacy and safety of valacyclovir over acyclovir - a study of 50 herpes zoster patients in FMCH, Faridpur. *Faridpur Med Coll J*. 2018;13(2):74-7.
 16. Lugito MDH, Pradono SA. Valacyclovir in the management of recurrent intraoral herpes infection. *J Dent Indones*. 2014; 21(1):27-31.