

## ***DYSPHAGIA IN CHILDREN WITH CEREBRAL PALSY AND THE ROLE OF FIBEROPTIC ENDOSCOPIC EVALUATION OF SWALLOWING (FEES): A REVIEW***

Joshua Runtuwene\*

<sup>a</sup> Department of Ear, Nose, Throat, Head and Neck Surgery  
Faculty of Medicine, Sam Ratulangi University, Manado

\*Corresponding author: [joshuaruntuwene@unsrat.ac.id](mailto:joshuaruntuwene@unsrat.ac.id)

### ***Abstract***

**Background:** Cerebral palsy (CP) is a neurological disorder that affects muscle control and coordination, often resulting in various physical and developmental challenges. Dysphagia poses a common challenge in children diagnosed with cerebral palsy, significantly impacting their ability to eat and swallow. The mechanisms of dysphagia in children with cerebral palsy can be multifactorial and involve several factors, including oral motor dysfunction, decreased muscle tone, gastroesophageal reflux, delayed or disorganized swallowing reflexes, sensory issues, and structural abnormalities. Accurate assessment of dysphagia is vital for effective management. **Aim:** This comprehensive review aims to provide a thorough explanation of dysphagia in pediatric CP, with a particular focus on the application of Fiberoptic Endoscopic Evaluation of Swallowing (FEES) as an evaluative tool. **Method:** A comprehensive search strategy was utilized to locate relevant studies from databases including PubMed Medline, Cochrane, Embase, Proquest, dan Scopus. **Results:** In cerebral palsy-related dysphagia, disruptions in muscle coordination and control during swallowing can result in significant complications. Early detection and intervention are vital to minimize adverse outcomes. FEES is a safe outpatient procedure used to assess swallowing in this condition, with abnormal findings including delayed swallow initiation, reduced tongue control and bolus manipulation, impaired velopharyngeal closure, reduced laryngeal elevation and closure, decreased epiglottic movement, pharyngeal residue, and signs of penetration or aspiration. **Conclusion:** Overall, FEES offers valuable insights into the swallowing function of these children and helps guide appropriate treatment interventions

**Keywords:** *dysphagia; FEES; children; cerebral palsy*

### ***Abstrak***

**Latar Belakang:** *Cerebral palsy* (CP) adalah gangguan neurologis yang mempengaruhi kontrol dan koordinasi otot sehingga mengakibatkan berbagai keterbatasan fisik dan gangguan perkembangan. Disfagia merupakan masalah pada anak-anak dengan CP, yang secara signifikan mempengaruhi kemampuan mereka dalam proses makan dan menelan. Mekanisme disfagia pada anak dengan cerebral palsy dapat bersifat multifaktorial dan melibatkan beberapa faktor, termasuk disfungsi motorik oral, penurunan tonus otot, refluks gastroesofagus, refleks menelan yang tertunda atau terganggu, masalah sensorik, dan kelainan struktural. Penilaian yang akurat terhadap disfagia sangat penting untuk tatalaksana yang efektif. **Tujuan:** memberikan penjelasan menyeluruh tentang disfagia pada anak dengan CP, yang khusus membahas penerapan *Fiberoptic Endoscopic Evaluation of Swallowing* (FEES) sebagai alat diagnostik dan evaluasi. **Metode:** Strategi pencarian komprehensif digunakan untuk menemukan studi yang relevan dari basis data meliputi: PubMed Medline, Cochrane, Embase, Proquest, dan Scopus. **Hasil:** Pada disfagia terkait CP, gangguan koordinasi dan kontrol otot saat menelan dapat menyebabkan komplikasi yang bermakna. Deteksi dan intervensi dini sangat penting untuk meminimalkan komplikasi lanjut. FEES merupakan prosedur rawat jalan yang aman digunakan untuk menilai kemampuan menelan, dengan temuan abnormal termasuk gangguan awal keterlambatan menelan, penurunan pengendalian lidah dan manipulasi bolus, gangguan penutupan velofaring, gangguan elevasi dan penutupan laring, gangguan pergerakan epiglotis, residu di faring, serta tanda-tanda penetrasi atau aspirasi. **Kesimpulan:** Secara keseluruhan, FEES bermanfaat dalam menilai fungsi menelan pada anak dengan CP dan membantu menentukan intervensi dan tatalaksana yang tepat.

Kata kunci: disfagia; FEES; anak-anak; cerebral palsy

## **INTRODUCTION**

Cerebral palsy (CP) encompasses a group of neurodevelopmental disorders due to non-progressive brain damage during development, resulting in disorders of movement and/or posture and of motor function. It is commonly observed in childhood and is the leading cause of physical disability. Swallowing difficulties, known as dysphagia, are prevalent in children with CP and can give rise to complications like aspiration pneumonia, malnutrition, and diminished quality of life (Sadowska et al., 2020a). The prevalence rates of cerebral palsy range from 1.5 to over 3 per 1000 live births, influenced by various factors, including gestational age, birth weight, the occurrence of multiple births, and the overall health conditions of mothers. Dysphagia in CP exhibits variable prevalence and epidemiological characteristics based on different populations studied and the criteria used to define dysphagia. Prevalence rates range widely, estimated to be between 19% and 99%, highlighting the heterogeneity of the condition (Sadowska et al., 2020a; Salghetti & Martinuzzi, 2012).

The specific type and severity of dysphagia can vary depending on the motor impairments and associated comorbidities present in each classification which lead to difficulties with sucking, chewing, controlling food or liquid in the mouth (Salghetti & Martinuzzi, 2012; Shamsoddini et al., 2014), and difficulties with initiating and maintaining the swallowing process (Monbaliu et al., 2017; Sadowska et al., 2020a; Salghetti & Martinuzzi, 2012). Untreated or inadequately managed dysphagia in children with CP can lead to various complications, including malnutrition, dehydration, aspiration pneumonia, weight loss, and impaired growth. These complications highlight the importance of early detection and intervention to minimize adverse outcomes (Patel et al., 2020; Van Den Engel-Hoek et al., 2015b). The prognosis for dysphagia in children with CP varies depending on the severity of neurological impairment, associated

comorbidities, and access to appropriate interventions. Early diagnosis, comprehensive treatment plans, and ongoing support from a multidisciplinary team can significantly improve feeding and swallowing outcomes and enhance the overall quality of life of the Children.

The accurate diagnosis and assessment of dysphagia are crucial for effective management. Fiberoptic Endoscopic Evaluation of Swallowing (FEES) is a real-time visualization procedure that allows for direct examination of the pharyngeal and laryngeal structures during swallowing (Langmore, 2006a; Willette et al., 2016). The camera on the endoscope allows the clinician to visualize the structures of the pharynx, larynx, and upper esophagus. FEES is a safe and well-tolerated procedure that can be performed in outpatient settings. The technique involves the insertion of a thin, flexible endoscope through the nasal passage to obtain a direct view of the swallowing process (Nacci et al., 2008). FEES is commonly used to assess various swallowing disorders, including dysphagia in children with cerebral palsy (Printza et al., 2022). This review aims to provide valuable insights into dysphagia in children with CP and delve into the utilization of FEES as a diagnostic tool specifically for this condition

## **METHOD**

A comprehensive search strategy will be utilized to locate relevant studies from various databases including PubMed Medline, Cochrane, Embase, Proquest, dan Scopus. Only studies that specifically address dysphagia in children with cerebral palsy and discuss the application of FEES will be considered for inclusion. The collected data will be thoroughly analyzed to identify recurring themes and patterns, while also critically assessing the quality and validity of the selected studies. By synthesizing and interpreting the findings, this review aims to provide a comprehensive understanding of dysphagia in children with cerebral palsy and evaluate the effectiveness of FEES as a diagnostic tool. The review will

adhere to appropriate citation and referencing guidelines to ensure proper acknowledgment of the sources.

## **RESULT AND DISCUSSION**

### **A. Dysphagia in Cerebral Palsy**

#### ***Definition***

Dysphagia in cerebral palsy refers to swallowing difficulties that are specifically associated with brain and neurological damage in cerebral palsy (Salghetti & Martinuzzi, 2012). This condition is characterized by disruptions in the coordination and control of the muscles involved in swallowing, which can lead to problems with oral intake, feeding, and overall nutrition (Smith et al., 2021; Sadowska et al., 2020b; Salghetti & Martinuzzi, 2012).

#### ***Etiology and Pathogenesis***

Dysphagia in cerebral palsy is caused by a complex interaction of neurological, anatomical, functional, gastrointestinal, and environmental variables. These factors can interact and impact one another, resulting in a distinct dysphagia profile in each cerebral palsy patient (Sadowska et al., 2020b; Salghetti & Martinuzzi, 2012).

##### **1. Neurological abnormalities**

Damage to the central nervous system, notably brain regions involved in motor control and coordination, plays a critical role in the development of dysphagia in cerebral palsy. Damage to the cerebral cortex, basal ganglia, brainstem, and cranial nerves can interfere with the neuronal connections and synchronization needed for successful swallowing (Maynard et al., 2020; Patel et al., 2020; Salghetti & Martinuzzi, 2012).

##### **2. Anatomical abnormalities**

Anatomical abnormalities in the oral and pharyngeal structures can contribute to dysphagia in cerebral palsy. These abnormalities may include malformations, structural asymmetry, orofacial muscle weakness or tightness, and skeletal deformities. Anatomical variations can

impact the coordination and movement of the muscles involved in swallowing, leading to difficulties in the oral and pharyngeal phases of swallowing (Sadowska et al., 2020b; Salghetti & Martinuzzi, 2012; Van Den Engel-Hoek et al., 2015a).

##### **3. Functional factors**

Functional impairments related to muscle tone, coordination, and control significantly contribute to dysphagia in cerebral palsy. Fluctuating muscle tone, such as hypertonia or hypotonia, can affect the timing, strength, and coordination of the muscles involved in swallowing. Weak or uncoordinated muscle contractions can result in difficulties with bolus formation, propulsion, and clearance (Sadowska et al., 2020b; Salghetti & Martinuzzi, 2012).

##### **4. Gastrointestinal factors**

Gastrointestinal factors, including gastroesophageal reflux disease (GERD) and impaired gastric motility, can further exacerbate dysphagia in cerebral palsy. GERD may contribute to esophageal irritation, aspiration, and feeding aversions. Delayed gastric emptying or gastrostomy tube dependence can also impact feeding and swallowing function (Asgarshirazi et al., 2017; Patel et al., 2020; Salghetti & Martinuzzi, 2012).

##### **5. Feeding Behavior and Environmental Factors**

Feeding behavior and environmental factors can influence dysphagia in cerebral palsy. These factors encompass a range of issues, including oral aversion, behavioral difficulties, poor positioning during feeding, inadequate feeding techniques, and limited access to appropriate nutritional support (Smith et al., 2021; Sadowska et al., 2020b; Salghetti & Martinuzzi, 2012).

The specific type and severity of dysphagia can vary depending on the motor impairments and associated comorbidities present in each classification. Here is an overview of dysphagia in different

classifications of cerebral palsy (Sadowska et al., 2020b; Salghetti & Martinuzzi, 2012):

1. **Spastic Cerebral Palsy.** Individuals with spastic cerebral palsy often experience dysphagia due to increased muscle tone and coordination difficulties. This spasticity can result from damage to the upper motor neurons, which are responsible for transmitting signals from the brain to the muscles. The disrupted neural signaling leads to abnormal muscle contractions, including hypertonia and increased resistance to movement, which can impact the precise coordination required for swallowing, causing issues with sucking, chewing, and controlling food or liquid in the mouth (Salghetti & Martinuzzi, 2012; Shamsoddini et al., 2014).
2. **Dyskinetic (Athetoid or Dystonic) Cerebral Palsy.** In dyskinetic cerebral palsy, the disruption of the basal ganglia and extrapyramidal motor pathways in the central nervous system contributes to the motor impairments and dysphagia. It is characterized by involuntary and uncontrolled movements, which can result to muscle tone fluctuations and abnormal movements affecting the coordination of swallowing. This can lead to difficulties with initiating and maintaining the swallowing process, as well as controlling the flow of food or liquid (Monbaliu et al., 2017; Sadowska et al., 2020a; Salghetti & Martinuzzi, 2012).
3. **Ataxic Cerebral Palsy.** Dysphagia in individuals with ataxic cerebral palsy is primarily related to problems with motor coordination and balance. It can manifest as difficulties in initiating and coordinating swallowing movements, resulting in disrupted timing and reduced precision during the swallowing process (Patel et al., 2020; Sadowska et al., 2020b).
4. **Mixed Type Cerebral Palsy.** Some individuals with cerebral palsy may have a mixed type, where multiple motor impairments are present. In these cases, dysphagia can encompass a combination of

the difficulties seen in different types of cerebral palsy. The severity and specific characteristics of dysphagia may vary depending on the predominant motor impairments within the mixed classification (Patel et al., 2020; Sadowska et al., 2020b; Salghetti & Martinuzzi, 2012).

### ***Diagnostic assessment***

Diagnosing dysphagia in children with CP requires a multidimensional approach, involving a combination of clinical observations, assessment findings, and objective test results (Sadowska et al., 2020b; Salghetti & Martinuzzi, 2012).

- a. **Screening and History Taking,** Screening tools, such as questionnaires and checklists, can help identify individuals at risk of dysphagia and guide further assessment. Detailed history taking is crucial, including information about include specific signs and symptoms of dysphagia, such as difficulty initiating swallowing, coughing or choking incidents during feeding, weight loss, recurrent respiratory infections, documented aspiration, or previous interventions (Patel et al., 2020; Sadowska et al., 2020b).
- b. **Physical Examination,** A comprehensive physical examination is performed to evaluate the orofacial structures, oral motor function, and overall coordination of swallowing. It includes assessment of cranial nerve function, lip closure, tongue control, jaw movement, gag reflex, and presence of structural abnormalities or muscle weakness (Patel et al., 2020; Sadowska et al., 2020b).
- c. **Instrumental Evaluations,** The two most commonly used instrumental evaluations for dysphagia in cerebral palsy are videofluoroscopic swallowing study (VFSS) and fiberoptic endoscopic evaluation of swallowing (FEES). VFSS provides real-time visualization of the swallowing process using fluoroscopy,

while FEES involves the insertion of a flexible endoscope to assess the pharyngeal phase of swallowing. Other useful tools including videoendoscopy, ultrasound, scintigraphy for oral stage assessment and pH-manometry for the oesophagus functional alteration assessment (Labeit et al., 2021; Langmore, 2006b; Matsuda et al., 2020; Willette et al., 2016).

- d. **Functional Assessments**, Functional assessments focus on the impact of dysphagia on daily activities, such as oral intake, feeding skills, and nutritional status. Functional assessments may include observation of mealtime behaviors, assessment of oral intake patterns, assessment of feeding skills and strategies, and evaluation of nutritional intake and growth (Langmore, 2006b; Van Den Engel-Hoek et al., 2015b; Willette et al., 2016).
- e. **Assessment Tools and Protocols**, Several assessment tools and protocols are available to guide the clinical assessment of dysphagia in cerebral palsy, including the Dysphagia Disorders Survey, Eating and Drinking Ability Classification System, and Pediatric Eating Assessment Tool, as well as condition-specific assessments designed for individuals with cerebral palsy (Labeit et al., 2021; Langmore, 2006b; Willette et al., 2016).
- f. **Multidisciplinary Approach**, The assessment of dysphagia in cerebral palsy requires a multidisciplinary approach involving speech-language pathologists, occupational therapists, dieticians, and medical specialists. Collaboration among team members is crucial to obtain a comprehensive understanding of the swallowing difficulties, develop appropriate interventions, and monitor progress over time (Labeit et al., 2021; Matsuo & Palmer, 2008; Nacci et al., 2008; Van Den Engel-Hoek et al., 2015a).

### ***Differential diagnosis***

Distinguishing dysphagia from other feeding difficulties in children with CP is essential. Differential diagnosis involves considering other possible causes, such as gastroesophageal reflux, upper airway obstruction, other neuromuscular disorders, anatomical abnormalities, or behavioral feeding disorders (Patel et al., 2020; Sadowska et al., 2020b; Salghetti & Martinuzzi, 2012).

### ***Treatment***

Mild cases may require adjustments in diet, while more severe cases may need specialized feeding positions, utensils, and texture modifications. In severe cases with persistent dysphagia signs, temporary cessation of oral feedings may be necessary, gastrostomy feeding is highly recommended in these cases. Nasogastric feedings can be used as a temporary measure before considering gastrostomy feeding. Severely affected children may require early and aggressive treatment to prevent growth failure. Short-term nasogastric feeding is commonly used to address weight loss, and gastrostomy feeding is recommended if weight deterioration continues (Monbaliu et al., 2017; Printza et al., 2022; Sadowska et al., 2020b; Salghetti & Martinuzzi, 2012; Shamsoddini et al., 2014).

### **B. Fiberoptic endoscopic evaluation of swallowing (FEES) for dysphagia assessment in children with cerebral palsy**

FEES involves the use of a flexible endoscope to visualize the pharyngeal and laryngeal structures during swallowing. It is a safe and well-tolerated procedure that can be performed in outpatient settings. The technique involves the insertion of a thin, flexible endoscope through the nasal passage to obtain a direct view of the swallowing process (Nacci et al., 2008). Before the procedure, the patient's medical history, symptoms, previous swallowing assessments are reviewed, and informed consent is taken. The patient is

positioned upright in a chair or at the bedside, with the head in a neutral position. The flexible endoscope is prepared, ensuring that it is clean and properly functioning. Topical anesthesia is applied to the nasal passages using a nasal spray or cotton swabs soaked in a local anesthetic. This helps to reduce discomfort during the passage of the endoscope through the nasal cavity. The endoscope, which is a thin, flexible tube with a light source and camera at its tip, is carefully inserted through one nostril and advanced along the nasal cavity until it reaches the posterior pharyngeal wall. Once the endoscope is in position, the swallowing evaluation begins. The camera on the endoscope allows the clinician to visualize the structures of the pharynx, larynx, and upper esophagus.

The patient is asked to perform various swallowing tasks, such as swallowing saliva, sips of water, or specific food consistencies. The clinician observes the coordination, timing, and efficiency of the swallowing process, as well as any signs of penetration or aspiration. During the swallowing evaluation, the clinician focuses on the pharyngeal phase of swallowing, which involves the movement of food or liquid from the mouth into the esophagus. The structures and functions evaluated include the velopharyngeal closure, laryngeal elevation and closure, epiglottic movement, and the opening and coordination of the upper esophageal sphincter. Throughout the procedure, the clinician records the findings and observations using video or images obtained from the endoscope (Dziewas et al., 2019; Printza et al., 2022; Willette et al., 2016).

Some common findings of dysphagia in cerebral palsy observed during FEES evaluation including (Dziewas et al., 2019; Labeit et al., 2021; Salghetti & Martinuzzi, 2012):

1. Delayed swallow initiation

One of the common findings in FEES evaluation is delayed initiation of the swallow. Individuals with cerebral palsy may have difficulty initiating the swallowing reflex in a timely manner,

leading to food or liquid remaining in the oral cavity for an extended period before the initiation of swallowing. This can be seen as residue or pooling of material in the oral cavity during the FEES evaluation. The FEES examination also allows the clinician to observe the timing of the pharyngeal swallow initiation. A delayed trigger refers to a delay in the onset of the pharyngeal swallow after the bolus reaches the pharynx. Delayed swallow initiation can also disrupt the coordination between the oral and pharyngeal phases of swallowing. The FEES test may reveal inconsistencies or inefficiencies in the timing and coordination of these phases (Labeit et al., 2021; Langmore, 2006b).

2. Reduced tongue control and bolus manipulation

FEES may reveal reduced tongue control and inadequate bolus manipulation in individuals with cerebral palsy. These individuals may exhibit difficulties in forming a cohesive bolus and moving it effectively through the oral cavity (Labeit et al., 2021; Langmore, 2006b, 2006a; Maynard et al., 2020; Willette et al., 2016).

a) Observation of tongue movement: reduced tongue control may be evident as weak, uncoordinated, or asymmetrical tongue movements. The tongue may struggle to manipulate the bolus effectively, leading to difficulties in forming a cohesive and well-controlled bolus.

b) Assessment of oral residue: in individuals with reduced tongue control, the incomplete manipulation of the bolus may result in residue remaining in the oral cavity. This residue can coat the oral structures, indicating difficulties in effectively clearing the bolus.

c) Identification of bolus fragmentation: FEES can identify bolus fragmentation, which occurs when the tongue fails to adequately manipulate and maintain the integrity of the bolus.

Fragmented boluses may not be cohesive and can lead to difficulties in propelling the bolus posteriorly for safe swallowing.

- d) Evaluation of oral transit time: reduced tongue control can result in prolonged oral transit time, meaning it takes longer for the bolus to move from the oral cavity to the pharynx. FEES assessment allows for the measurement of oral transit time, which can help identify delays in the swallowing process.
  - e) Analysis of mastication patterns: FEES can also provide insights into mastication patterns in individuals with cerebral palsy. Impaired mastication, such as inadequate chewing or inefficient breakdown of solid foods, can contribute to bolus inconsistency and hinder the overall swallowing process. FEES assessment can reveal any difficulties in mastication that may be present.
3. Impaired velopharyngeal closure
- Velopharyngeal closure refers to the closure of the opening between the nasal and oral cavities during swallowing. FEES can identify inadequate velopharyngeal closure, which may result in nasal regurgitation or aspiration of food or liquid into the nasal cavity (Labeit et al., 2021; Langmore, 2006b; Printza et al., 2022).
- a) Observation of velopharyngeal movement: during the FEES evaluation, the clinician closely observes the movement of the velum (soft palate) and the posterior pharyngeal wall during swallowing. Impaired velopharyngeal closure may be evident as inadequate or incomplete closure of the velum against the posterior pharyngeal wall.
  - b) Visualization of nasal regurgitation: FEES allows for the direct visualization of nasal regurgitation, which occurs when food or liquid enters the nasal cavity during swallowing due to insufficient velopharyngeal closure. The presence of nasal regurgitation during the FEES examination indicates impaired velopharyngeal closure.
- c) Detection of aspiration: in cases of impaired velopharyngeal closure, there is an increased risk of aspiration, where food or liquid enters the airway instead of passing into the esophagus. FEES can help identify signs of aspiration, such as material entering the larynx or beyond, leading to coughing, throat clearing, or changes in vocal quality.
  - d) Assessment of residue in the nasopharynx: inadequate velopharyngeal closure can result in residue or pooling of food or liquid in the nasopharynx after swallowing. FEES evaluation allows for the visualization of residue in the nasopharynx, indicating incomplete clearance of the swallowed material.
  - e) Evaluation of timing and coordination: FEES assessment also includes an analysis of the timing and coordination of velopharyngeal closure with other swallowing events. Impaired velopharyngeal closure may disrupt the normal sequence of swallowing, leading to delays or inefficiencies in the pharyngeal phase of swallowing.
4. Reduced Laryngeal Elevation and Closure
- Laryngeal elevation and closure are crucial for protecting the airway during swallowing. FEES may show reduced laryngeal elevation and incomplete closure of the vocal folds, increasing the risk of penetration or aspiration of food or liquid into the airway (Labeit et al., 2021; Langmore, 2006b, 2006a; Printza et al., 2022; Van Den Engel-Hoek et al., 2015b).
- a) Observation of laryngeal movement: During the FEES evaluation, the clinician closely observes the movement of the larynx during swallowing. Reduced laryngeal elevation may be evident as inadequate

upward movement of the larynx during the swallowing process. This can result in the larynx not reaching the appropriate height to facilitate the closure of the airway.

- b) Evaluation of vocal fold closure: FEES allows for direct visualization of the vocal folds during swallowing. Reduced laryngeal closure may be observed as incomplete or delayed closure of the vocal folds. Inadequate closure of the vocal folds can lead to material entering the airway, increasing the risk of aspiration.
- c) Detection of penetration and aspiration: FEES can identify signs of penetration and aspiration during swallowing. Penetration refers to the entry of food or liquid into the laryngeal vestibule without passing beyond the vocal folds, while aspiration occurs when material passes below the vocal folds and enters the airway. Reduced laryngeal elevation and closure can contribute to these events, which can be observed during the FEES examination.
- d) Assessment of residue in the laryngeal area: in cases of reduced laryngeal elevation and closure, residue or pooling of food or liquid may be present in the laryngeal area after swallowing. FEES evaluation allows for the visualization of residue in the larynx or the valleculae and pyriform sinuses, indicating incomplete clearance of the swallowed material.
- e) Evaluation of timing and coordination: FEES assessment includes an analysis of the timing and coordination of laryngeal elevation and closure with other swallowing events. Reduced laryngeal elevation and closure can disrupt the normal sequence of swallowing, leading to delays or inefficiencies in the pharyngeal phase of swallowing.

#### 5. Reduced Epiglottic Movement

The epiglottis plays a key role in protecting the airway by covering the opening to the larynx during swallowing. Dysfunction of the vagus nerve (X) related to cerebral palsy can result in reduced or impaired epiglottic movement (Langmore, 2006a; Matsuo & Palmer, 2008). FEES can reveal reduced or impaired epiglottic movement, which can result in penetration or aspiration of food or liquid into the airway (Labeit et al., 2021; Langmore, 2006b; Printza et al., 2022; Van Den Engel-Hoek et al., 2015b).

- a) Observation of epiglottic movement: During the FEES evaluation, the clinician closely observes the movement of the epiglottis during swallowing. Reduced epiglottic movement may be evident as inadequate folding or closure of the epiglottis over the larynx, leading to incomplete protection of the airway during swallowing.
- b) Visualization of penetration and aspiration: FEES allows for the direct visualization of material entering the airway during swallowing. Reduced epiglottic movement can result in the inadequate closure of the epiglottis, allowing food or liquid to penetrate into the airway or pass below the level of the vocal folds, leading to aspiration.
- c) Examination of pharyngeal residue: In cases of reduced epiglottic movement, residue or pooling of food or liquid may be present in the pharynx after swallowing. FEES evaluation allows for the visualization of residue in the valleculae and pyriform sinuses, indicating incomplete clearance of the swallowed material due to inadequate epiglottic movement.
- d) Assessment of pharyngeal transit time: FEES assessment also includes an analysis of the timing and coordination of epiglottic movement with other swallowing events. Reduced epiglottic movement can result in delays in the



closure of the epiglottis and subsequent clearance of the bolus from the pharynx, leading to prolonged pharyngeal transit time.

6. Residue in the Pharynx

FEES may demonstrate the presence of food or liquid residue in the pharynx after swallowing. This indicates inefficient clearance of the swallowed material from the pharynx, increasing the risk of aspiration or subsequent swallowing difficulties (Costa et al., 2021; Labeit et al., 2021; Langmore, 2006b; Printza et al., 2022).

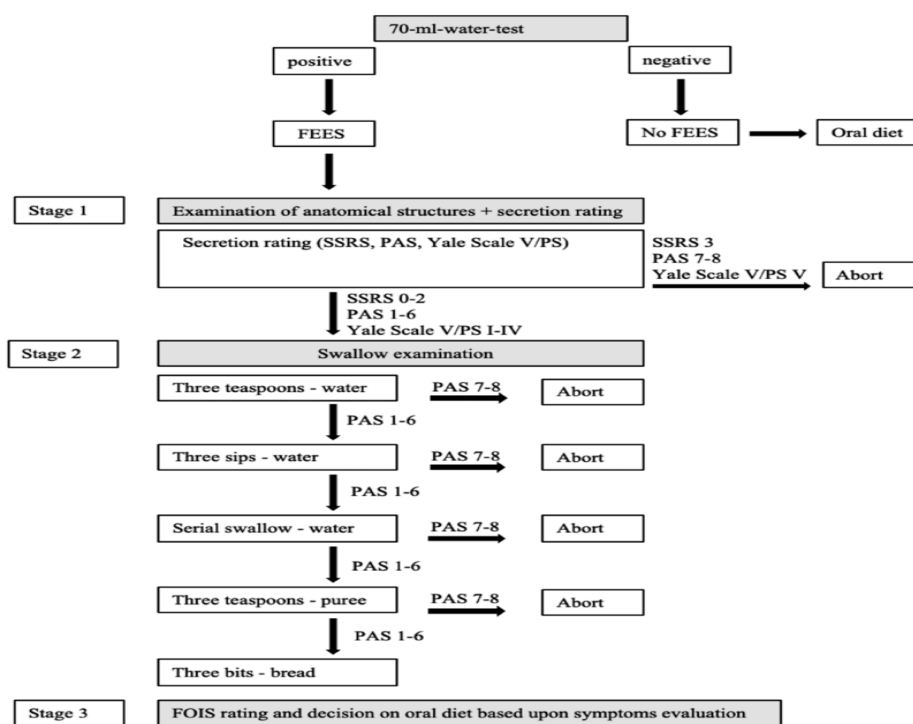
- a) Visualization of pharyngeal residue: during the FEES assessment, the clinician carefully examines the pharynx after swallowing to identify the presence and location of residue.
- b) Identification of specific anatomical areas with residue: the clinician observes areas such as the valleculae (spaces between the base of the tongue and the epiglottis) and the pyriform sinuses (spaces adjacent to the larynx) for the presence of residue. By identifying the specific areas where residue tends to accumulate, targeted interventions can be developed to address the issue.
- c) Assessment of pharyngeal muscle function and coordination: weakness or impaired coordination of the

pharyngeal muscles can contribute to inadequate clearance of the bolus, leading to residue formation. The clinician assesses the strength and coordination of these muscles to determine their impact on residue.

- d) Analysis of timing and coordination: disruptions in the normal sequence of swallowing events can result in residue in the pharynx. The FEES assessment helps identify any timing or coordination issues that may contribute to residue formation.
  - e) Assessment of sensory function: impaired sensation in the pharynx can affect the individual's ability to detect and clear residue. The clinician can observe the response of the pharyngeal structures to sensory stimulation during the FEES assessment.
7. Signs of Penetration or Aspiration
- FEES allows for the direct visualization of the penetration or aspiration of food or liquid into the airway. The clinician can observe signs such as coughing, throat clearing, or changes in vocal quality that indicate the entry of material into the larynx or beyond. Ranges from no visible secretions anywhere in the hypopharynx to some transient secretion bubbles visible in the valleculae and pyriform sinuse (Costa et al., 2021; Labeit et al., 2021; Langmore, 2006b; Printza et al., 2022).

**Table 1.** Scoring Criteria for Pathological Findings in FEES Dysphagia Evaluation

<b>Murray's Secretion Severity Rating Scale (SSRS)</b> (Kuo et al., 2017)	
a.	0: Normal (no secretions)
b.	1: Pooling in valleculae/pyriform sinus
c.	2: Pooling in laryngeal vestibule transiently
d.	3: Pooling in laryngeal vestibule consistently
<b>Yale's Pharyngeal Residue Severity Rating Scale (YPRSRS)</b> (Neubauer et al., 2015)	
e.	0% (none)
f.	1-5% (trace)
g.	5-25% (mild)
h.	25-50% (moderate)
i.	>50% (severe)
<b>Penetration Aspiration Scale (PAS)</b> (Alkhuwaiter et al., 2022)	
j.	1: None
k.	2: Penetration with clearing
l.	3: Penetration without clearing
m.	4: Material contacts true vocal folds with clearing
n.	5: Material contacts true vocal folds without clearing
o.	6: Aspiration with spontaneous clearance
p.	7: Aspiration without clearance
<b>Fiberoptic Endoscopic Dysphagia Severity Scale (FEDSS)</b> (Warnecke et al., 2009)	
q.	1: Soft solid food – No penetration/aspiration and not more than mild to moderate residues in valleculae or pyriforms
r.	2: Soft solid food – Penetration/aspiration or massive residues in valleculae or pyriforms
s.	3: Liquid – Penetration with sufficient protective reflex
t.	4: Liquid – Penetration/aspiration without or insufficient protective reflex
u.	4: Puree – Penetration with sufficient protective reflex
v.	5: Puree – Penetration/aspiration without or insufficient protective reflex
w.	6: Saliva – Penetration/aspiration



**Figure 1.** FEES methodology. (SSRS secretion severity rating scale, PAS penetration- aspiration-scale, Yale Scale V/PS yale pharyngeal residue severity rating scale, V valleculae, PS Piriform sinus) (Everton et al., 2020)

The FOIS (Functional Oral Intake Scale) is a rating scale used to assess the functional level of oral intake in individuals with dysphagia (Matsuda et al., 2020). It provides a standardized method for evaluating the severity of dysphagia and determining the appropriate diet and feeding recommendations. The FOIS scale consists of seven levels, ranging from

total dependence on non-oral feeding (Level 1) to complete independence with regular oral diet and no restrictions (Level 7). Each level represents a different degree of functional oral intake ability and reflects the individual's ability to safely consume food and liquids by mouth (Dziewas et al., 2019; Everton et al., 2020; Matsuda et al., 2020).

**Tabel 2.** Functional Oral Intake Scale (FOIS) (Matsuda et al., 2020)

Level	Description
1	Nothing by mouth (NPO) - The individual is unable to safely consume any food or liquids by mouth and requires complete dependence on non-oral feeding methods, such as tube feeding.
2	Tube-dependent with minimal oral intake - The individual primarily relies on tube feeding for nutrition but may tolerate some minimal amounts of food or liquids by mouth.
3	Tube-dependent with supplemental oral intake - The individual continues to require tube feeding for the majority of their nutrition but can also consume larger volumes of food or liquids by mouth as a supplement.
4	Total oral intake with significant modifications - The individual can safely consume a full diet by mouth, but with significant modifications such as texture modifications, limited food choices, or special feeding techniques.
5	Total oral intake with multiple consistencies, some limitations - The individual can safely consume a full diet by mouth with multiple consistencies (e.g., solid, liquid), but with some limitations or restrictions.
6	Total oral intake with minor limitations - The individual can consume a full diet by mouth without significant limitations but may have minor difficulties or restrictions related to specific food textures or consistencies.
7	Total oral intake with no restrictions - The individual can consume a full diet by mouth without any limitations or restrictions.

While FEES is a valuable diagnostic tool for assessing swallowing disorders, it does have certain limitations that should be considered. Some of these limitations include (Labeit et al., 2021; Langmore, 2006b; Printza et al., 2022):

1. Lack of visualization of the oral phase: FEES primarily focuses on the pharyngeal and laryngeal phases of swallowing, which may limit the assessment of oral phase abnormalities. The inability to directly visualize the oral cavity and the initial stages of swallowing may result in incomplete information about the overall swallowing function.
2. Limited assessment of esophageal function: FEES primarily evaluates the structures and functions of the pharynx and larynx but does not provide direct information about esophageal function. Therefore, it may not detect underlying esophageal abnormalities

that could contribute to dysphagia or aspiration.

3. Difficulty in assessing sensory deficits: FEES primarily provides visual information and may not fully capture sensory deficits that can impact swallowing function. Sensory impairments, such as reduced or absent laryngeal sensation, may go undetected during FEES, potentially leading to an incomplete understanding of the individual's swallowing abilities.
4. Limited assessment of bolus characteristics: FEES primarily focuses on the anatomical and physiological aspects of swallowing but may not provide detailed information about the properties of the bolus (e.g., viscosity, texture). Bolus characteristics can significantly impact swallowing function, and their assessment may require additional methods such as modified barium swallow studies.

5. Difficulty in assessing swallow function during non-oral intake: FEES primarily evaluates swallowing during oral intake, and assessing swallow function during non-oral feeding methods (e.g., tube feeding) may be challenging. This limitation may hinder the complete understanding of the individual's swallowing abilities across different feeding modalities.
6. Operator dependence and variability: FEES assessments require skilled and experienced operators who can accurately interpret the findings. Inter-rater variability and differences in interpretation may affect the consistency and reliability of the assessment results.
7. Lack of standardized scoring systems: Unlike videofluoroscopic swallow studies (VFSS), FEES does not have widely accepted standardized scoring systems for assessing dysphagia severity or predicting the risk of penetration or aspiration. This can make it challenging to compare and interpret results across different assessment.

## CONCLUSION

Dysphagia in cerebral palsy refers to disruptions in the coordination and control of the muscles involved in swallowing, specifically associated with cerebral palsy, a neurodevelopmental disorder caused by brain damage or abnormalities. Fiberoptic endoscopic evaluation of swallowing (FEES) is a valuable tool for diagnosing dysphagia in children with cerebral palsy. It is considered a safe and cost-effective procedure that offers a direct visualization of the pharyngeal and laryngeal structures, allowing for the identification of anatomical abnormalities and assessment of swallowing coordination. Ultimately, FEES provides important insights into dysphagia-related issues in cerebral palsy and can be complemented with other assessment methods for a comprehensive evaluation

## REFERENCES

- Alkhuwaiter, M., Davidson, K., Hopkins-Rossabi, T., & Martin-Harris, B. (2022). Scoring the Penetration–Aspiration Scale (PAS) in Two Conditions: A Reliability Study. *Dysphagia*, 37(2), 407. <https://doi.org/10.1007/S00455-021-10292-6>.
- Asgarshirazi, M., Farokhzadeh-Soltani, M., Keihanidost, Z., & Shariat, M. (2017). Evaluation of Feeding Disorders Including Gastro-Esophageal Reflux and Oropharyngeal Dysfunction in Children With Cerebral Palsy. *Journal of Family & Reproductive Health*, 11(4), 197. [/pmc/articles/PMC6168757/](https://pubmed.ncbi.nlm.nih.gov/3168757/).
- Costa, A., Martin, A., Arreola, V., Riera, S. A., Pizarro, A., Carol, C., Serras, L., & Clavé, P. (2021). Assessment of swallowing disorders, nutritional and hydration status, and oral hygiene in students with severe neurological disabilities including cerebral palsy. *Nutrients*, 13(7). <https://doi.org/10.3390/NU13072413/S1>.
- Dziewas, R., auf dem Brinke, M., Birkmann, U., Bräuer, G., Busch, K., Cerra, F., Damm-Lunau, R., Dunkel, J., Fellgiebel, A., Garms, E., Glahn, J., Hagen, S., Held, S., Helfer, C., Hiller, M., Horn-Schenk, C., Kley, C., Lange, N., Lapa, S., ... Warnecke, T. (2019). Safety and clinical impact of FEES – Results of the FEES-registry. *Neurological Research and Practice*, 1(1), 1–8. <https://doi.org/10.1186/S42466-019-0021-5/FIGURES/3>.
- Everton, L. F., Benfield, J. K., Hedstrom, A., Wilkinson, G., Michou, E., England, T. J., Dziewas, R., Bath, P. M., & Hamdy, S. (2020). Psychometric assessment and validation of the dysphagia severity rating scale in stroke patients. *Scientific Reports*, 10(1). <https://doi.org/10.1038/S41598-020-64208-9>.
- Introduction - Interventions for Feeding and Nutrition in Cerebral Palsy - NCBI Bookshelf*. (n.d.). Retrieved 2 June 2023, from

<https://www.ncbi.nlm.nih.gov/books/NBK132431/>.

Kuo, C. W., Allen, C. T., Huang, C. C., & Lee, C. J. (2017). Murray secretion scale and fiberoptic endoscopic evaluation of swallowing in predicting aspiration in dysphagic patients. *European Archives of Oto-Rhino-Laryngology : Official Journal of the European Federation of Oto-Rhino-Laryngological Societies (EUFOS) : Affiliated with the German Society for Oto-Rhino-Laryngology - Head and Neck Surgery*, 274(6), 2513–2519. <https://doi.org/10.1007/S00405-017-4522-Y>

Labeit, B., Ahring, S., Boehmer, M., Sporns, P., Sauer, S., Claus, I., Roderigo, M., Suntrup-Krueger, S., Dziewas, R., Warnecke, T., & Muhle, P. (2021). Comparison of Simultaneous Swallowing Endoscopy and Videofluoroscopy in Neurogenic Dysphagia. *Journal of the American Medical Directors Association*. <https://doi.org/10.1016/j.jamda.2021.09.026>

Langmore, S. E. (2006a). Endoscopic evaluation of oral and pharyngeal phases of swallowing. *GI Motility Online, Published Online: 16 May 2006; | Doi:10.1038/Gimo28*. <https://doi.org/10.1038/GIMO28>.

Langmore, S. E. (2006b). Endoscopic evaluation of oral and pharyngeal phases of swallowing. *GI Motility Online, Published Online: 16 May 2006; | Doi:10.1038/Gimo28*. <https://doi.org/10.1038/GIMO28>.

Matsuda, Y., Karino, M., & Kanno, T. (2020). Relationship between the functional oral intake scale (Fois) and the self-efficacy scale among cancer patients: A cross-sectional study. *Healthcare (Switzerland)*, 8(3). <https://doi.org/10.3390/HEALTHCARE8030269>.

Matsuo, K., & Palmer, J. B. (2008). Anatomy and Physiology of Feeding and Swallowing – Normal and Abnormal. *Physical Medicine and Rehabilitation Clinics of North*

*America*, 19(4), 691. <https://doi.org/10.1016/J.PMR.2008.06.001>.

Maynard, T. M., Zohn, I. E., Moody, S. A., & Lamantia, A. S. (2020). Suckling, Feeding, and Swallowing: Behaviors, Circuits, and Targets for Neurodevelopmental Pathology. *Annual Review of Neuroscience*, 43, 315. <https://doi.org/10.1146/ANNUREV-NEURO-100419-100636>

Monbaliu, E., Himmelmann, K., Lin, J. P., Ortibus, E., Bonouvrié, L., Feys, H., Vermeulen, R. J., & Dan, B. (2017). Clinical presentation and management of dyskinetic cerebral palsy. *The Lancet. Neurology*, 16(9), 741–749. [https://doi.org/10.1016/S1474-4422\(17\)30252-1](https://doi.org/10.1016/S1474-4422(17)30252-1).

Nacci, A., Ursino, F., La Vela, R., Matteucci, F., Mallardi, V., & Fattori, B. (2008). Fiberoptic endoscopic evaluation of swallowing (FEES): proposal for informed consent. *Acta Otorhinolaryngologica Italica*, 28(4), 206. [/pmc/articles/PMC2644994/](https://doi.org/10.1016/j.pmc/articles/PMC2644994/).

Neubauer, P. D., Rademaker, A. W., & Leder, S. B. (2015). The Yale Pharyngeal Residue Severity Rating Scale: An Anatomically Defined and Image-Based Tool. *Dysphagia*, 30(5), 521–528. <https://doi.org/10.1007/S00455-015-9631-4>.

Patel, D. R., Neelakantan, M., Pandher, K., & Merrick, J. (2020). Cerebral palsy in children: a clinical overview. *Translational Pediatrics*, 9(Suppl 1), S125. <https://doi.org/10.21037/TP.2020.01.01>

Printza, A., Sdravou, K., & Triaridis, S. (2022). Dysphagia Management in Children: Implementation and Perspectives of Flexible Endoscopic Evaluation of Swallowing (FEES). *Children*, 9(12). <https://doi.org/10.3390/CHILDREN9121857>.

Sadowska, M., Sarecka-Hujar, B., & Kopyta, I. (2020a). Cerebral Palsy: Current Opinions on Definition, Epidemiology, Risk

Factors, Classification and Treatment Options. *Neuropsychiatric Disease and Treatment*, 16, 1505. <https://doi.org/10.2147/NDT.S235165>.

Salghetti, A., & Martinuzzi, A. (2012). Dysphagia in cerebral palsy. *Eastern Journal of Medicine*, 17, 188–193.

Shamsoddini, A., Amirsalari, S., Hollisaz, M.-T., Rahimnia, A., & Khatibi-Aghda, A. (2014). Management of Spasticity in Children with Cerebral Palsy. *Iranian Journal of Pediatrics*, 24(4), 345. [/pmc/articles/PMC4339555/](https://pubmed.ncbi.nlm.nih.gov/264339555/).

Van Den Engel-Hoek, L., De Groot, I. J. M., De Swart, B. J. M., & Erasmus, C. E. (2015a). Feeding and Swallowing Disorders in Pediatric Neuromuscular Diseases: An Overview. *Journal of Neuromuscular Diseases*, 2(4), 357. <https://doi.org/10.3233/JND-150122>.

Warnecke, T., Ritter, M. A., Kröger, B., Oelenberg, S., Teismann, I., Heuschmann, P. U., Ringelstein, E. B., Nabavi, D. G., & Dziewas, R. (2009). Fiberoptic endoscopic Dysphagia severity scale predicts outcome after acute stroke. *Cerebrovascular Diseases (Basel, Switzerland)*, 28(3), 283–289. <https://doi.org/10.1159/000228711>.

Willette, S., Molinaro, L. H., Thompson, D. M., & Schroeder, J. W. (2016). Fiberoptic examination of swallowing in the breastfeeding infant. *The Laryngoscope*, 126(7), 1681–1686. <https://doi.org/10.1002/LARY.25641>