

Role of Endoscopic Procedure in Foreign Body (Button Battery) Ingestion in Children: A Case Report

Harsali Lampus,¹ Candy,¹ Leo Rendy,¹ Andy A. Rangan²

¹Division of Pediatric Surgery, Department of Surgery, Faculty of Medicine, Universitas Sam Ratulangi - Prof. Dr. R. D. Kandou Hospital, Manado, Indonesia

²Specialist Study Program of Department of Surgery, Faculty of Medicine, Universitas Sam Ratulangi – Prof. Dr. R. D. Kandou Hospital, Manado, Indonesia

Email: AndyRangan@gmail.com

Received: January 26, 2023; Accepted: July 9, 2023; Published online: July 12, 2023

Abstract: Foreign body (FB) ingestion is a common problem especially in children below the age of 5 years. Due to the extensive use of batteries as power supply in electronic gadgets, cases of button battery ingestion have become more common. If a button battery was found in the stomach of a child under the age of five, it should be assessed for esophageal injury and removed endoscopically, if at all possible, within 24 to 48 hours. We reported a 3-year-old boy who swallowed a foreign body three hours before being admitted to the hospital. Initially the patient was playing with robot toys that used batteries, then a battery of the robots was accidentally swallowed. The patient had no symptoms and physical examinations showed no abnormalities. Abdominal X-ray examination revealed a foreign body located in the stomach. The patient underwent endoscopic foreign body removal but no foreign body was found until the second part of duodenum. Therefore, an exploratory laparotomy was performed, and the foreign body, a button battery, was removed from the ileum. In conclusion, since endoscopic foreign body removal failed to remove the foreign body in this patient, an exploratory laparotomy was performed and through antimesenteric ileotomy, the foreign body, a button battery, was successfully removed.

Keywords: foreign body; endoscopic foreign body removal; exploratory laparotomy

INTRODUCTION

Foreign body (FB) ingestion is a common problem especially in children below the age of 5 years. Coins, jewelry, toy components, and batteries are frequently ingested by kids. Children between the ages of 6 months and 3 are the most common age range for FB consumption.¹ Due to the extensive usage of these batteries as power supply in electronic gadgets, cases of button battery ingestion have become more common.²

Children between the ages of six months and three years represent the majority of foreign body ingestions.³ Repeated episodes and the ingestion of various foreign objects are rare events that typically affect kids with behavioral issues or developmental delays. Even though the mortality rate from ingesting a foreign body is incredibly low, deaths have been documented.⁴

Ingested FBs may eventually pass on their own, or patients may develop problems like erosions, ulceration, and perforations. But when a battery becomes trapped in the esophagus, it poses a serious medical problem that needs to be treated right once. Battery ingestion in particular can be fatal. Serious problems and sequelae have been observed despite early removal.⁵ The recommendation by the North American Society for Pediatric Gastro-enterology, Hepatology, and Nutrition (NASPGHAN) Endoscopy Committee is if the FB a button battery, it must be removed in under two hours. If a button battery was found in the stomach of a child under the age of five, it should be assessed for esophageal injury and removed endoscopically, if at all possible, within 24 to 48 hours.

Damage to the esophageal mucosa itself can result in long-term scarring and esophageal stricture formation. One of the more dreaded complications is erosion into the aorta or other major blood vessels, resulting in massive hemorrhage and death. Other complications include vocal cord paralysis from damage to recurrent laryngeal nerves, thyroid parenchymal hemorrhage, and spondylodiscitis of the spine, among others.⁶

Based on the increased cases of foreign body ingestion among children and its dreaded complications, we are encouraged to present a case report of a 3-year-old boy who had swallowed a foreign object since three hours before being admitted to the hospital.

CASE REPORT

We reported a 3-year-old boy who had swallowed a foreign object three hours before being admitted to the hospital. Initially the patient was playing with robot toys that used button batteries. According to the patient's mother, the swallowed battery was a flat round battery with a size of more than 2 cm. The patient had no symptoms, and physical examinations showed no abnormalities found.

Abdominal X-Ray showed visible foreign body in the stomach (Fig. 1). Moreover, chest X-ray (standing position) showed visible shadow of round opaque (foreign body), suspected in the stomach/intestine (Fig. 2). The patient underwent endoscopic extraction of the FB but endoscopy revealed no FB until the second part of duodenum so far; therefore, exploration laparotomy was performed on this patient. Through antimesenteric ileotomy, the FB, a button battery, was successfully removed.

DISCUSSION

Ingestion of button batteries and foreign bodies (FB) is on the rise among children. Foreign body ingestion is a common problem especially among children below the age of 5 years. Coins, jewelry, toy components, and batteries are frequently ingested by children between the ages of 6 months and 3 years.¹ Due to the extensive usage of these batteries as power supply in electronic gadgets, button battery ingestion has become more common among others.²

More than 75% of more than 100,000 instances of foreign body ingestion recorded each year in the United States involve children.⁷ Children between the ages of six months and three years

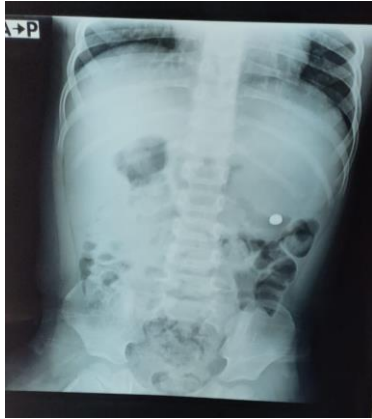

Figure 1. Abdominal X-Ray showed visible foreign body in the stomach.

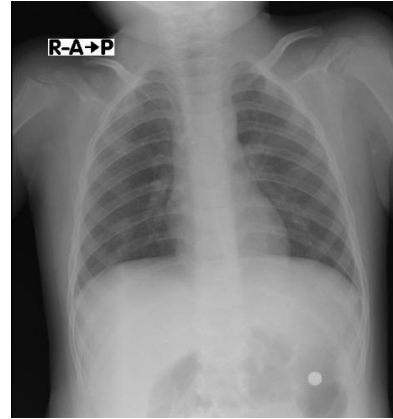


Figure 2. Chest X-ray (standing position) showed visible shadow of round opaque (foreign body), suspected in the stomach/intestine

represent the majority of foreign body ingestions.³ Repeated episodes and the ingestion of various foreign objects are rare events that typically affect children with behavioral issues or developmental delays. Even though the mortality rate from ingesting a foreign body is incredibly low, deaths have been documented.⁴ Coins, button batteries, toys, toy pieces, magnets, safety pins, screws, marbles, bones, and food boluses are some of the often ingested foreign objects.^{7,8}

In this case, we reported a 3-year-old child who had accidentally swallowed a foreign object since 3 hours before being admitted to the hospital. The patient had no symptoms and physical examinations showed no abnormalities found. Such cases could either show no symptoms or serious problems that need immediate medical care.⁹ Ingested FBs may eventually pass on their own, or patients may develop problems like erosions, ulceration, and perforations. However, when a battery becomes trapped in the esophagus, it poses a serious medical problem that needs to be treated right once. Battery ingestion in particular can be fatal. Serious problems and sequelae have been observed despite early removal. In contrast, it has been deemed to pose little harm when it is found in the stomach. It is advised to observe for at least 24 to 48 hours because various digestive juices and enzymes in gastric acid and gastrointestinal tract can neutralize alkaline substances released by the battery, which reduce the corrosive effect of batteries.^{5,6,7}

Abdominal x-ray examination revealed the battery foreign body located in the stomach. The recommendations for the timing of endoscopic intervention have recently undergone revisions by the North American Society for Pediatric Gastroenterology, Hepatology, and Nutrition (NASPGHAN) Endoscopy Committee.¹⁰ If the foreign body is a button battery, it must be removed in under two hours. The patient may be observed for up to 24 hours if no symptoms are present. Regardless of the lack of symptoms, lengthy objects should be vomited out within 24 hours if they are swallowed. If a button battery was found in the stomach of a child under the age of five, it should be assessed for esophageal injury and removed endoscopically, if at all possible, within 24 to 48 hours. Consider outpatient observation if the patient is 5 years or older or the battery diameter is less than 2 cm.

Repeat radiography in 48 hours is advised for children aged 5 and older who have ingested a battery with a diameter of less than 2 cm. Patients 5 years of age or younger who have swallowed a battery less than 2 cm should also be given the option of having an X-ray repeated if they are unable to evacuate the object in their stool within 10 to 14 days of ingesting it. Endoscopic removal is required if gastrointestinal symptoms develop or the battery does not pass the stomach by the time the X-ray is repeated.¹⁰ However, the majority of button batteries with a diameter of less than 2 cm in the stomach pass naturally and without any issues. It is advised that a battery with a diameter of less than 2 cm be removed if it is left in the pylorus or duodenum for an extended period of time.⁶

Initial management of button battery ingestion should include an assessment of the patient's age, type, and size of the battery when ingestion occurred, and where it is currently located. Low-risk, asymptomatic patients with batteries that have passed through the esophagus have a low risk of significant morbidity or mortality. Current recommendations include consideration of early endoscopy in high-risk patients (age less than 5 years or batteries greater than 20 mm) over concerns for unrecognized esophageal injury during passage into the stomach.⁷ The patient underwent endoscopic removal of the FB until conversion was possible, however no FB was found. Because of that it was decided to do an exploratory laparotomy. At the time of exploratory laparotomy, the FB, a button battery, was found in the ileum.

Endoscopic removal is preferred as it allows direct visualization of tissue injury. When a child exhibits symptoms, more than one battery is ingested, or when a magnet is also ingested, batteries in the stomach should be removed as quickly as possible. Endoscopic removal is carried out in cases of asymptomatic children if the battery still there after 24 hours, with a follow-up X-ray to confirm passage especially in situations when the timing of intake is unknown. In 94% of patients, endoscopy successfully removed the battery.¹¹ After endoscopic failure, rigid esophagoscopy was required to remove the FB. When endoscopic excision of an FB in the upper portion of the esophagus is unsuccessful, an otolaryngologist will do a rigid esophagoscopy. In contrast, some publications state that rigid esophagoscopy is mostly used to remove FBs.¹² In a recent Dutch investigation,¹³ 12.5% of batteries were surgically removed.

Instances of a button battery in the esophagus have frequently been linked to serious consequences, such as aorto-esophageal fistula and vocal cord paralysis.¹⁴ Poorer outcomes were found by Litovitz et al¹⁵ for lithium batteries with large diameters (2 cm) and in young children. They did not distinguish between button batteries in the stomach and esophagus and recommended that even if symptoms seem mild, endoscopic removal should still be taken into account. They also advised getting an X-ray within 4 days of ingestion if a child under the age of 6 is asymptomatic and the ingested battery is 1.5 cm in diameter or larger. However, if the patient is older than 6 years or the ingested battery is smaller than 1.5 cm, it can be treated at home, and it can be determined that the battery has passed by looking at the stool afterwards.

The mechanisms of battery-induced injury have been described: an alkaline electrolyte leak, electrical current production that hydrolyzes tissue fluids and creates hydroxide when it comes into contact with physiological solutions, and physical pressure necrosis on surrounding tissues. Despite the fact that heavy metals were absorbed systemically, no serious side effects such renal or hepatotoxicity were reported.⁴ The danger of injury is also higher for new batteries than for used batteries. Even lithium batteries smaller than 2 cm in diameter have a higher rate of serious injuries, which may suggest that the injury is caused by the higher voltage rather than a leak in the alkaline electrolyte or an electrical current.

There have been reports of lethal massive blood loss via aorto-oesophageal fistula, trachea-oesophageal fistula formation, oesophageal and tracheal stenoses, vocal cord paralysis, empyema, and spondylodiscitis as complications from button battery impaction.^{16,17} Damage to the esophageal mucosa itself can result in long-term scarring and esophageal stricture formation. Perforation of the esophagus can lead to pneumothorax, pneumomediastinum, mediastinitis, or tracheoesophageal fistula formation.¹² One of the more dreaded complications is erosion into the aorta or other major blood vessel, resulting in massive hemorrhage and death. Other complications include vocal cord paralysis from damage to recurrent laryngeal nerves, thyroid parenchymal hemorrhage, and spondylodiscitis of the spine, among others.⁶ Current recommendations include consideration of early endoscopy in high-risk patients (age less than 5 years or batteries greater than 20 mm) over concerns for unrecognized esophageal injury during passage into the stomach.

CONCLUSION

Foreign body ingestion is a common problem especially in children below the age of 5 years, however, if a battery was found in the stomach of a child under the age of five, it should be assessed

for esophageal injury and removed endoscopically, if at all possible, within 24 to 48 hours. Endoscopic removal is preferred as it allows direct visualization of tissue injury. Albeit, since endoscopic foreign body removal failed to remove the foreign body in this patient, an exploratory laparotomy was performed and through antimesenterial ileotomy, the foreign body, a button battery, was successfully removed.

Conflict of Interest

The authors affirm no conflict of interest in this study.

REFERENCES

1. Diaconescu S, Gimiga N, Sarbu I, Stefanescu G, Olaru C, Ioniuc I, et al. Foreign bodies ingestion in children: experience of 61 cases in a pediatric gastroenterology unit from Romania. *Gastroenterol Res Pract*. 2016;2016:1982567. Doi: 10.1155/2016/1982567.
2. Gan RWC, Nasher O, Jackson PB, Singh SJ. Diagnosis of button battery ingestion by “halo” radiographic sign: an exception to the rule. *BMJ Case Rep*. 2015;2015:bcr2015209908. Doi: 10.1136/bcr-2015-209908.
3. Wallace B, Landman MP, Prager J, Friedlander J, Kulungowski AM. Button battery ingestion complications. *J Pediatr Surg Case Reports*. 2017;19:1e3.
4. Yardeni D, Yardeni H, Coran AG, Golladay ES. Severe esophageal damage due to button battery ingestion: Can it be prevented? *Pediatr Surg Int*. 2004;20(7):496-501. Doi: 10.1007/s00383-004-1223-6.
5. Thomson M, Sharma S. The hazards of button battery ingestion. *Arch Dis Child*. 2015;100(11):1010-1. Doi: 10.1136/archdischild-2015-308313.
6. Jatana KR, Litovitz T, Reilly JS, Koltai PJ, Rider G, Jacobs IN. Pediatric button battery injuries: 2013 task force update. *Int J Pediatr Otorhinolaryngol*. 2013;77(9):1392-9.
7. Kramer RE, Lerner DG, Lin T, Manfredi M, Shah M, Stephen TC, et al. Management of ingested foreign bodies in children: A clinical report of the NASPGHAN endoscopy committee. *J Pediatr Gastroenterol Nutr*. 2015;60(4):562-74. Doi: 10.1097/MPG.0000000000000729.
8. Sharieff GQ, Brousseau TJ, Bradshaw JA, Shad JA. Acute esophageal coin ingestions: Is immediate removal necessary? *Pediatr Radiol*. 2003;33(12):859-63. Doi: 10.1007/s00247-003-1032-4. .
9. Sharpe SJ, Rochette LM, Smith GA. Pediatric battery-related Emergency Department visits in the United States, 1990-2009. *Pediatrics*. 2012;129(6):1111-7. Doi: 10.1542/peds.2011-0012.
10. Mirshemirani A, Khaleghnejad-Tabari A, Kouranloo J, Sadeghian N, Rouzrokh M, Roshanzamir F, et al. Clinical evaluation of disc battery ingestion in children. *Middle East J Dig Dis*. 2012;4(2):107-10.
11. Lisi G, Illiceto MT, Romeo EF, Lauriti G, Faraci S, Lombardi G, et al. Esophageal retained lithium battery in children younger than 6 years: A prompt structured multidisciplinary approach is essential to reduce long-term consequences. *Pediatr Emerg Care*. 2021;37(6):e295-e300.
12. Krom H, Visser M, Hulst JM, Wolters VM, Van den Neucker AM, de Meij T, et al. Serious complications after button battery ingestion in children. *Eur J Pediatr*. 2018;177(7):1063-70. Doi: 10.1007/s00431-018-3154-6
13. Rosenfeld EH, Sola R, Yu Y, St. Peter SD, Shah SR. Battery ingestions in children: variations in care and development of a clinical algorithm. *J Pediatr Surg*. 2018;53(8):1537-41.
14. El-Barghouty N. Management of disc battery ingestion in children. *Br J Surg*. 1991;78(2):247.
15. Simonin M, D’Agostino I, Lebreton M, Jughon O, Hamza J, Oualha M. Bilateral vocal palsy following coin cell lithium battery ingestion: a case report and review. *Eur J Pediatr*. 2013; 172(7):991-3. Doi: 10.1007/s00431-012-1899-x
16. Kieu V, Palit S, Wilson G, Ditchfield M, Buttery J, Burgner D, et al. Cervical spondylodiscitis following button battery ingestion. *J Pediatr*. 2014;164(6):1500.
17. Litovitz T, Whitaker N, Clark L, White NC, Narsolek M. Emerging battery-ingestion hazard: clinical implications. *Pediatrics*. 2010;125(6):1168-77. Doi: 10.1542/peds.2009-3037.